

AAO-PAAO Joint Meeting, San Francisco, CA, October 25-27, 2009



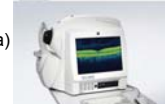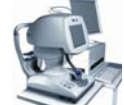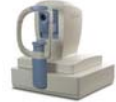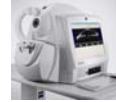Anterior Segment Imaging: Surgical Guidance

David Huang, MD, PhD
 Charles C. Manger III, MD Chair of Corneal Laser Surgery
 Assoc. Prof. of Ophthalmology & Biomedical Engineering
 Doheny Eye Institute,
 University of Southern California

Financial Interests:
 Optovue, Inc.: stock options, patent royalty, travel, grant
 Carl Zeiss Meditec, Inc.: patent royalty

Anterior Segment Optical Coherence Tomography Systems

- Time Domain
 - Zeiss Visante
 - Heidelberg SL-OCT (slitlamp-mounted)
- Fourier Domain
 - Optovue RTVue (retina+cornea)
 - Tomey SS-1000 CASIA
 - Zeiss Cirrus (retina+cornea)



Fourier v. Time Domain OCT

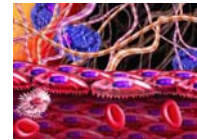


Technology	Time domain (Zeiss Visante)	Fourier domain (Optovue RTVue)
Speed	2000 A-scan/sec	26,000 A-scan/sec

David Huang, MD, PhD www.COOLab.net

Long v. Short Wavelength Infrared

- Shorter wavelength gives finer resolution
- Longer wavelength gives deeper penetration for angle and scleral imaging



Technology	Visante	RTVue
Axial resolution (FWHM cornea)	17 μm	5 μm
Wavelength	1310 nm	830 nm

David Huang, MD, PhD www.COOLab.net

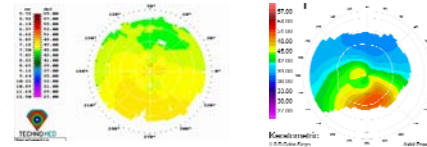


Yan Li, PhD

Keratoconus Screening

Forme fruste keratoconus is the most important risk factor for post-LASIK corneal ectasia

Binder P, Analysis of ectasia after LASIK: risk factors, *J Cat Refract Surg* 33:1530, 2007



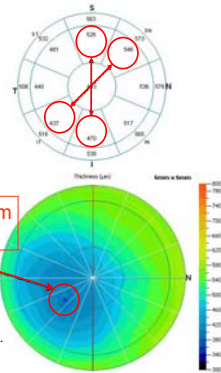
Topography does not screen out all eyes at risk

Topography	Normal	Suspicious	Abnormal	Total
# Ectasia Cases	25	27	33	93
Percent	27%	29%	41%	100%

Randieman JB et al. Risk assessment for ectasia after corneal refractive surgery. *Ophthalmol* 2007; 115:37-50

Detecting Keratoconic Thinning with OCT Pachymetric Indices

- General thinning
 - Min
- Focal thinning
 - Minimum - median
- Inferotemporal thinning
 - I-S
 - IT-SN
 - Y location of the Min




Li Y, Meisler M, Tang M, Lu A, Thakrar V, Reiser B, Huang D. Keratoconus diagnosis with optical coherence tomography pachymetry mapping. *Ophthalmology* 2008;115:2159-2166.

Combining OCT pachymetry indices improves keratoconus diagnosis

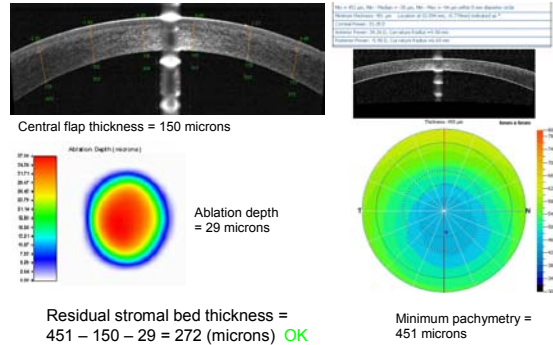
Parameter	1% Cutoff	Sensitivity	Specificity
IT - SN	< -52 μm	0.673	0.993
I - S	< -54 μm	0.561	0.986
Min	< 464 μm	0.649	1.000
Min-median	< -33 μm	0.839	0.986
Min location	Y < -1.1 mm	0.415	0.979
1 Abnormal		0.907	0.958
2 Abnormal		0.824	0.986

* Optovue RTVue database based on 143 normal and 205 keratoconus eyes from David Huang, MD, PhD; Robert Brass, MD; Yaron Rabinowicz, MD

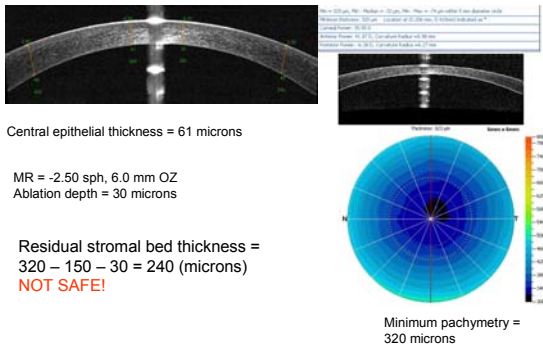


Planning Laser Vision Correction

Planning LASIK Retreatment



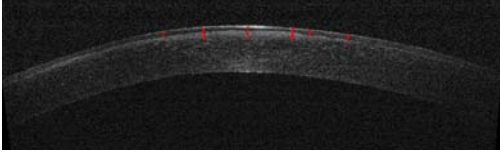
Planning PRK Retreatment



Yan Li, PhD

Guiding Phototherapeutic Keratectomy

Epithelial Thickness and Opacity Depth Measurements on OCT

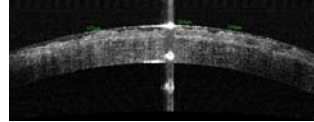


	1	2	3	4	5	6	7	8
Red measurement bar (micron)	61	143	162	148	73	75		
Corneal thickness at the red measurement bar (micron)	576	577	583	590	594	603		
Distance to the vertex (mm)	-1.1	-0.6	0.0	0.6	0.8	1.3		

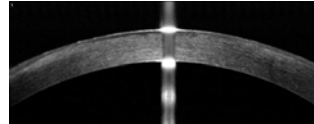
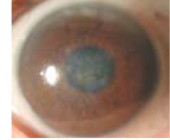David Huang, MD, PhD www.COOLLab.net

OCT Is Useful in The Planning of PTK Example: Reis Buckler Dystrophy

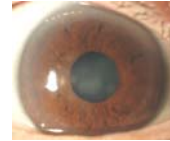
Opacity:200 μ m; CCT:680 μ m



Pre-PTK
BSCVA
20/100



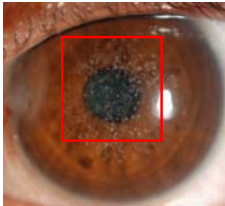
Post-PTK
BSCVA
20/40




David Huang, MD, PhD www.COOLLab.net

Granular Corneal Dystrophy

Slit-lamp photo

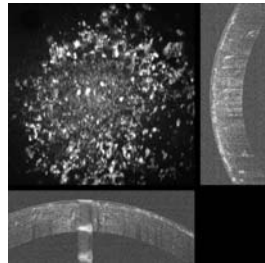


OCT projection



David Huang, MD, PhD www.COOLLab.net

PTK + PRK Simulation



- Transepithelial PTK
6.5/0.5 mm
AZ/TZ circle,
76 μ m
- PRK
-2.00 D, 6mm,
24 μ m

David Huang, MD, PhD www.COOLLab.net



Maocong Tang,
PhD

Corneal Power Measurement and Intraocular Lens Power Calculation

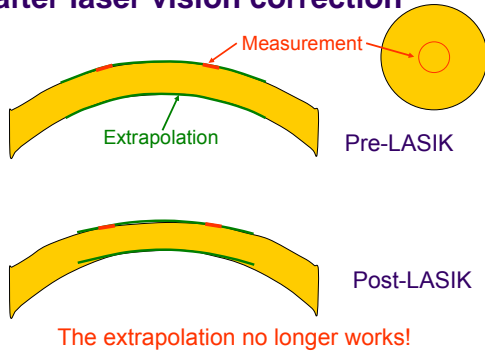


IOL calculation after laser vision correction is less accurate.

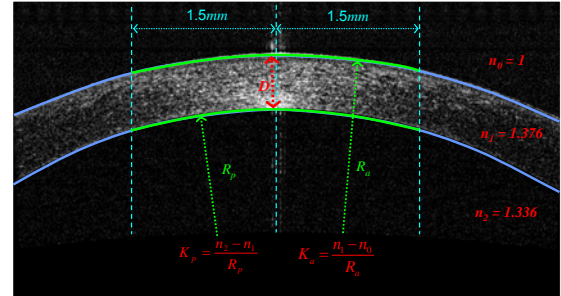
Group	Post-LASIK	Control
Within 1 D of emmetropia	30%	90%
Mean absolute deviation	1.3 D	0.6 D

Cataract surgery results using the clinical history method.
Randleman JB et al. *Cornea*. 2002; 21:751

The problem with keratometry after laser vision correction



Net corneal power combines anterior & posterior curvature measurements from OCT sections of corneal meridians



David Huang, MD, PhD www.COOLLab.net

Corneal power can be repeatably measured with OCT

Category	Number of eyes	Pooled STDEV (D)
Normal	38	0.19
Post-LASIK	16	0.26
Keratoconus	16	0.30
Scar	6	0.57

David Huang, MD, PhD www.COOLLab.net

OCT corneal power outperformed other methods in IOL power calculation

Method	# Eyes	Single-K SRK/T		Single-K Hoffer Q		Double-K Holladay II	
		MAE (D)	Range (D)	MAE (D)	Range (D)	MAE (D)	Range (D)
IOL-Master K	13	2.24	(-4.6, 1.4)	1.50	(-3.5, 0.8)	1.20	(-2.9, 0.89)
RGP K	11	2.20	(-5.1, 3.0)	1.86	(-4.1, 3.8)	1.70	(-3.5, 4.1)
Clinical History	11	1.35	(-3.7, 1.5)	1.35	(-2.8, 1.6)	1.44	(-2.3, 2.1)
OCT K	13	1.10	(-3.9, 0.9)	0.87	(-2.7, 1.6)	1.02	(-2.1, 1.9)

MAE = mean absolute error
 Prediction error = Predicted MRSE - Measured MRSE 1 month after surgery
 13 eyes of 11 cataract patient who had myopic LASIK
 Unpublished study performed at the Doheny Eye Institute

David Huang, MD, PhD www.COOLLab.net

Scheimpflug Camera Systems for Corneal & IOL Power Calculations

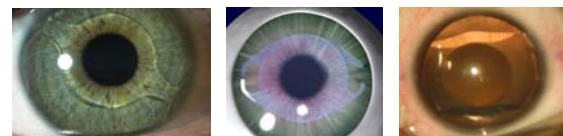


Oculus Pentacam



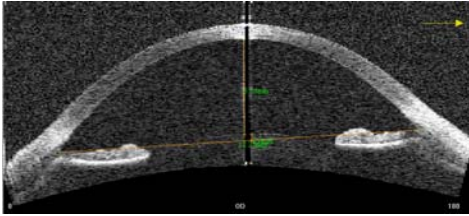
Ziemer Galileo

Savini G et al. JCRS 200 35;1193




Planning of Phakic Refractive Intraocular Lens Implantation

Measurement of Anterior Chamber Depth and Width



- Anterior chamber depth must be >3.0-3.2 mm, depending on IOL
- OCT (shown), ultrasound, slit-scanning tomography, Scheimpflug camera, or partial coherence biometry could be used

Endothelial Cell Density



- Preoperative endothelial density must be > 1900-3875 cells/mm², depending on IOL and age
- Confocal microscopy (Nidek Confoscan 4 image on left) or specular microscopy could be used

Huang D et al. Ophthalmic technology assessment: phakic intraocular lens implantation for the correction of myopia, a report by the American Academy of Ophthalmology, *Ophthalmology* 2009 in press

Some OCT functions presented are not yet FDA-approved

- RTVue Keratoconus Diagnosis Normative Reference
 - International software release November 2010
 - FDA approval pending
- RTVue Corneal Power
 - International software release November 2010
 - FDA approval pending
- PTK Simulation
 - Experimental software not FDA approved

Acknowledgements



R01 EY018184

Guiding The Treatment of Anterior Eye Diseases with Optical Coherence Tomography

www.COOLLab.net



PDF handout is posted on www.COOLLab.net